



Dr. Edoardo Verna

Dpt Cardiology

Ospedale di Circolo & Fondazione Macchi - University of Insubria, Varese, Italy

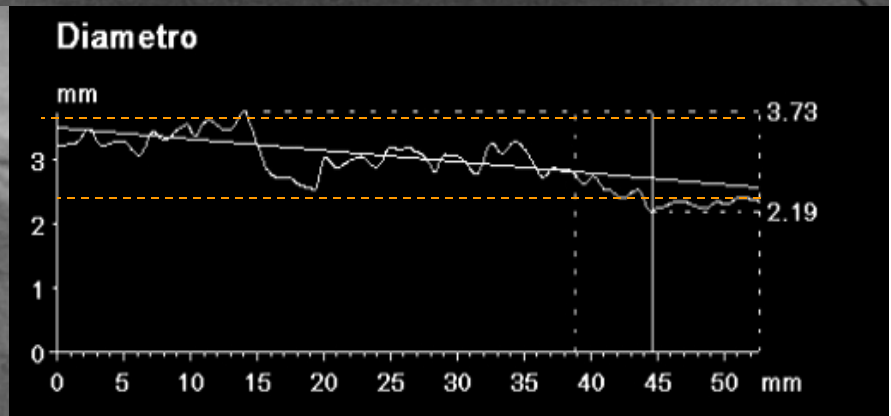
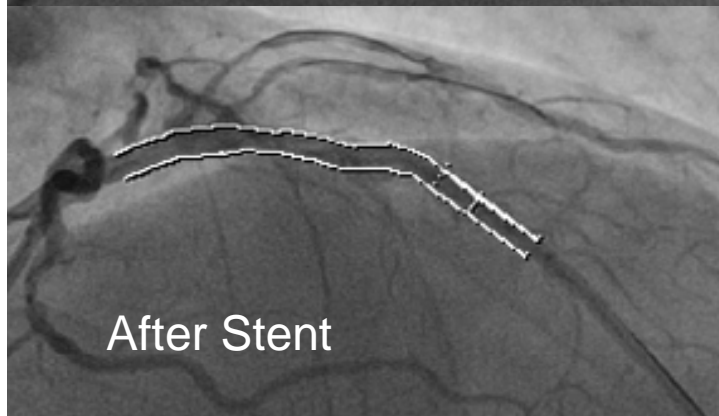
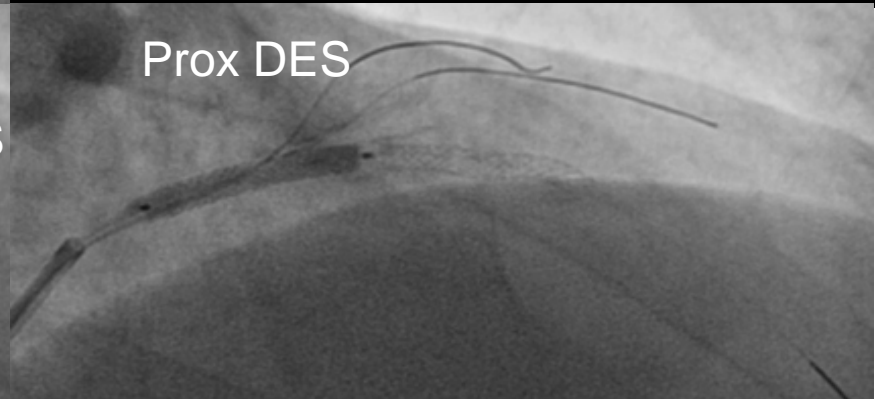
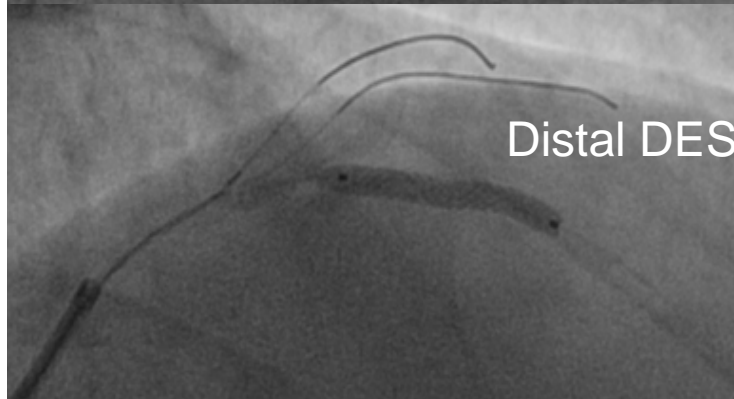
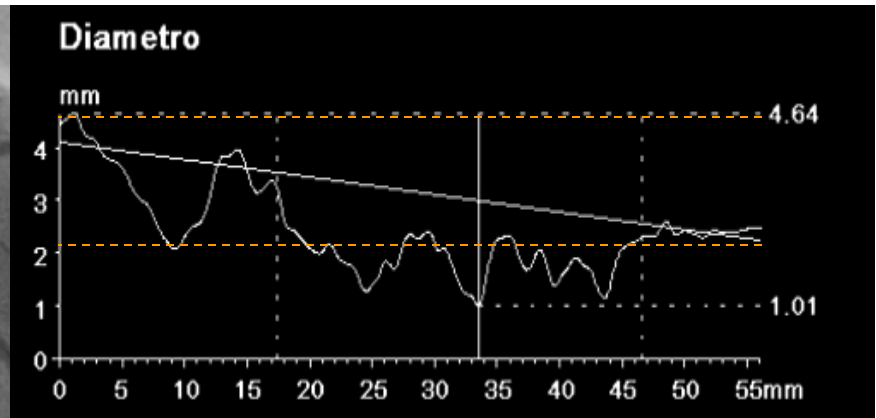
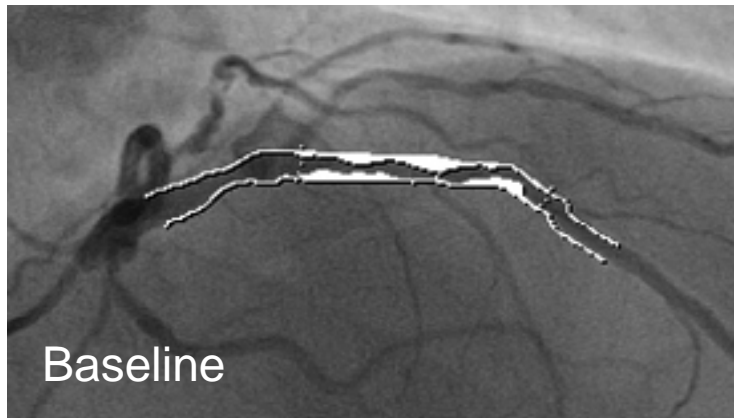
Stent Post-Dilatation of long Coronary artery Lesions with a *“conic balloon”*

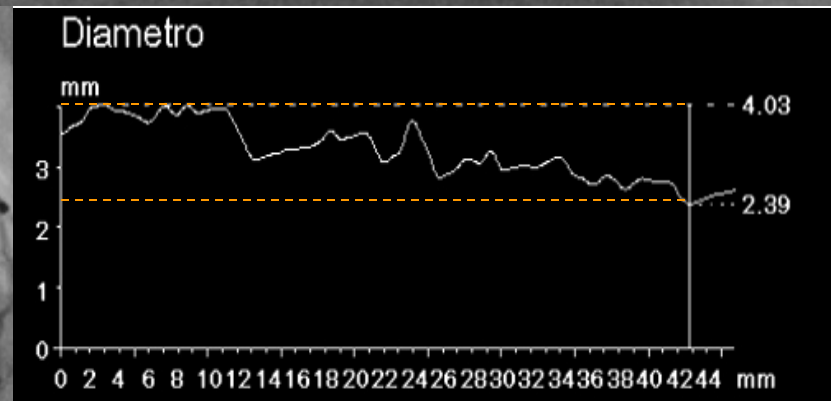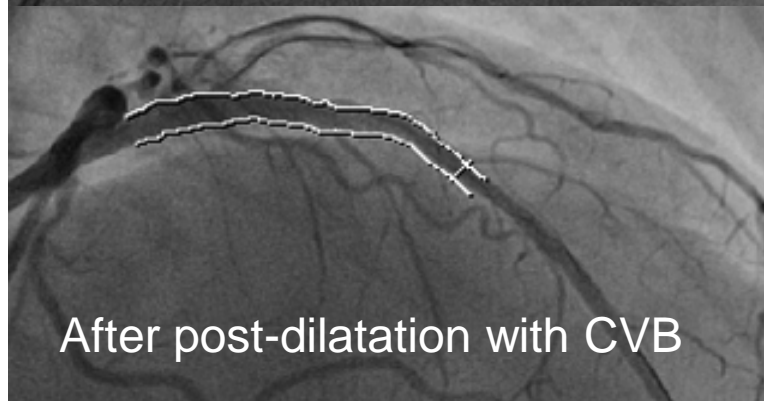
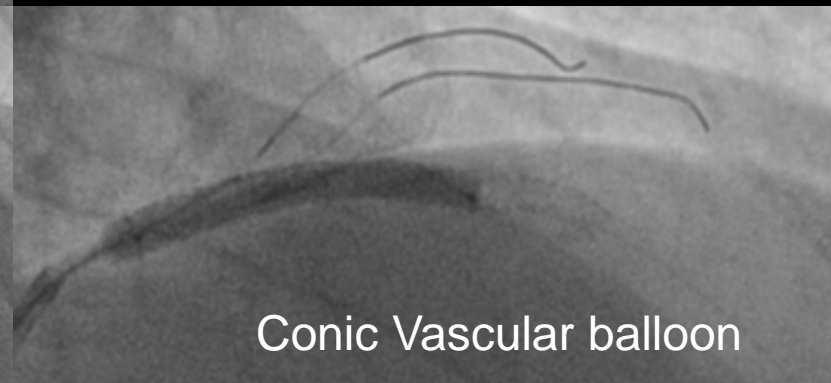
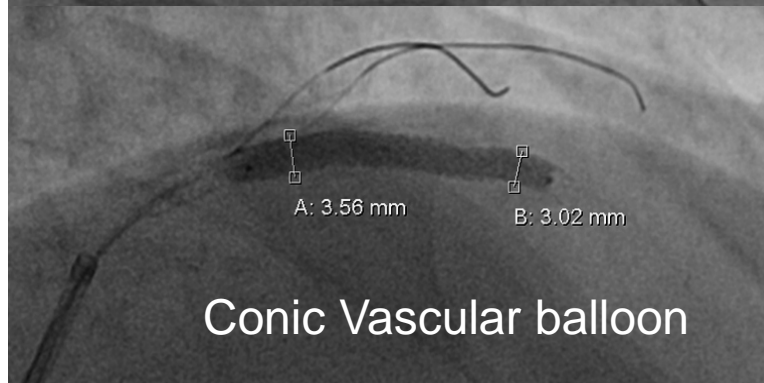
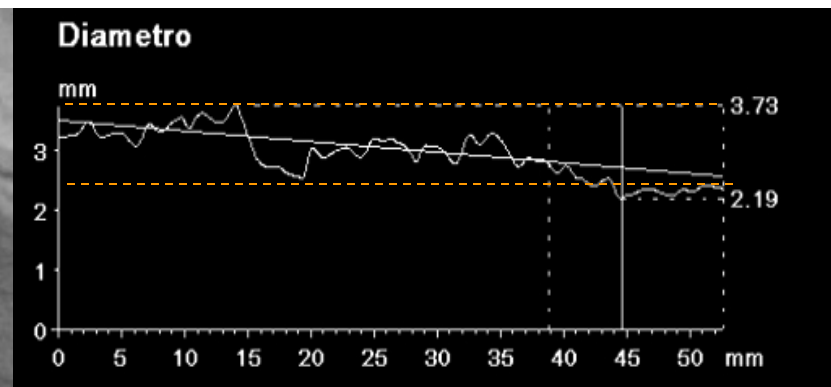
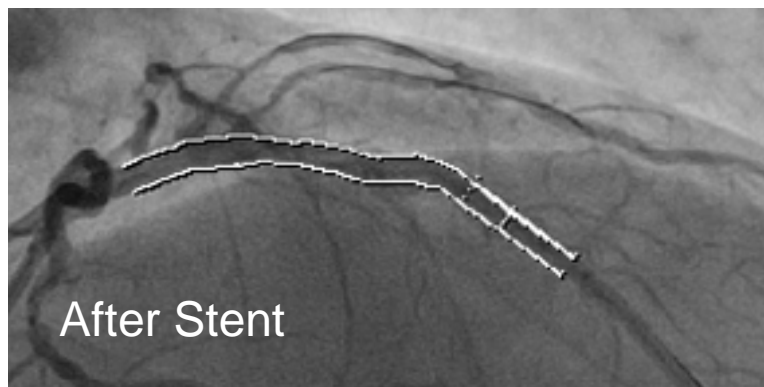
56 years old male

Prior inferior wall STEMI -> PCI of RCA (BMS) 2003

Recurrent chest pain

“significant” Multivessel CAD progression





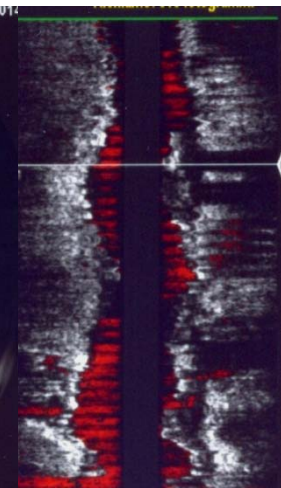
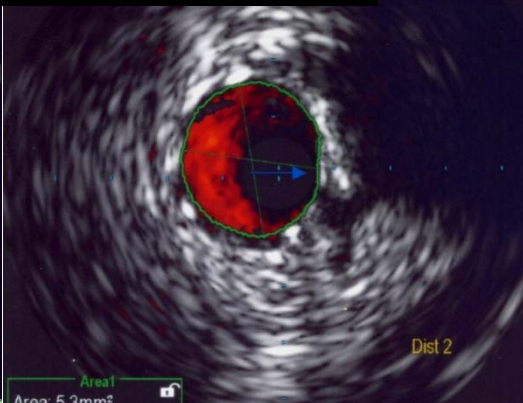
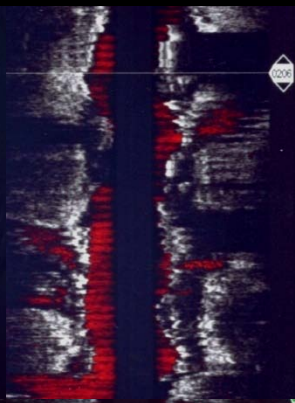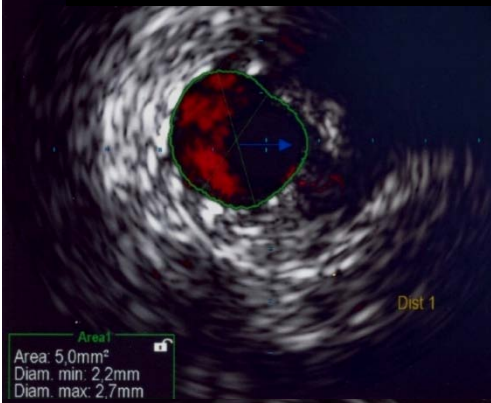
Stent before post-dilation

After *Conic Vascular* Balloon post-dilation

distal

MLA 5.0 mm²

MLA 5.3 mm²



Proximal

MLA 7.0 mm²

MLA 9.8 mm²

